

ACHQC Quality Improvement Summit 2024

Todd S. Harris
Newport Beach, CA

Disclosure:

Medtronic



SESSION 3: FIRESIDE CHAT WITH OUR HIGH PERFORMERS - INGUINAL HERNIA OUTCOMES VIDEO LEARNING

Moderators: Kaela Blake, MD & Lindsee McPhail, MD

11:15 AM	Robotic Inguinal Hernia	Rana Higgins, MD
11:30 AM	Shouldice	Michael Reinhorn, MD
11:45 AM	Open Preperitoneal	Nora Fullington, MD
12:00 PM	TEPP	Todd Harris, MD
12:15 PM	Lichtenstein	Alan Kravitz, MD

SESSION 3: FIRESIDE CHAT WITH OUR HIGH PERFORMERS - INGUINAL HERNIA OUTCOMES VIDEO LEARNING

Moderators: Kaela Blake, MD & Lindsee McPhail, MD



11:15 AM Robotic Inguinal Hernia

Rana Higgins, MD

11:30 AM Shouldice

Michael Reinhorn, MD

11:45 AM Open Preperitoneal

Nora Fullington, MD

12:00 PM TEPP

Todd Harris, MD

12:15 PM Lichtenstein

Alan Kravitz, MD

SESSION 3: FIRESIDE CHAT WITH OUR HIGH PERFORMERS - INGUINAL HERNIA OUTCOMES VIDEO LEARNING

Moderators: Kaela Blake, MD & Lindsee McPhail, MD

11:15 AM Robotic Inguinal Hernia

Rana Higgins, MD

11:30 AM Shouldice

Michael Reinhorn, MD

11:45 AM Open Preperitoneal

Nora Fullington, MD

12:00 PM TEPP

Todd Harris, MD

12:15 PM Lichtenstein

Alan Kravitz, MD



SESSION 3: FIRESIDE CHAT WITH OUR HIGH PERFORMERS - INGUINAL HERNIA OUTCOMES VIDEO LEARNING

Moderators: Kaela Blake, MD & Lindsee McPhail, MD

11:15 AM Robotic Inguinal Hernia

Rana Higgins, MD

11:30 AM Shouldice

Michael Reinhorn, MD

11:45 AM Open Preperitoneal

Nora Fullington, MD

12:00 PM TEPP

Todd Harris, MD

12:15 PM Lichtenstein

Alan Kravitz, MD



SESSION 3: FIRESIDE CHAT WITH OUR HIGH PERFORMERS - INGUINAL HERNIA OUTCOMES VIDEO LEARNING

Moderators: Kaela Blake, MD & Lindsee McPhail, MD

11:15 AM	Robotic Inguinal Hernia	Rana Higgins, MD
11:30 AM	Shouldice	Michael Reinhorn, MD
11:45 AM	Open Preperitoneal	Nora Fullington, MD
12:00 PM	TEPP	Todd Harris, MD
12:15 PM	Lichtenstein	Alan Kravitz, MD



SESSION 3: FIRESIDE CHAT WITH OUR HIGH PERFORMERS - INGUINAL HERNIA OUTCOMES VIDEO LEARNING

Moderators: Kaela Blake, MD & Lindsee McPhail, MD

11:15 AM	Robotic Inguinal Hernia	Rana Higgins, MD
11:30 AM	Shouldice	Michael Reinhorn, MD
11:45 AM	Open Preperitoneal	Nora Fullington, MD
12:00 PM	TEPP	Todd Harris, MD
12:15 PM	Lichtenstein	Alan Kravitz, MD



Why consider adding TEPP back into your repertoire?

1. Time is money
2. Pressures from the insurance carriers

Technical topics

1. Two layers of transversalis fascia
2. Balloon dissection

Are decreases in reimbursement making you take a hard look at how to become more efficient?

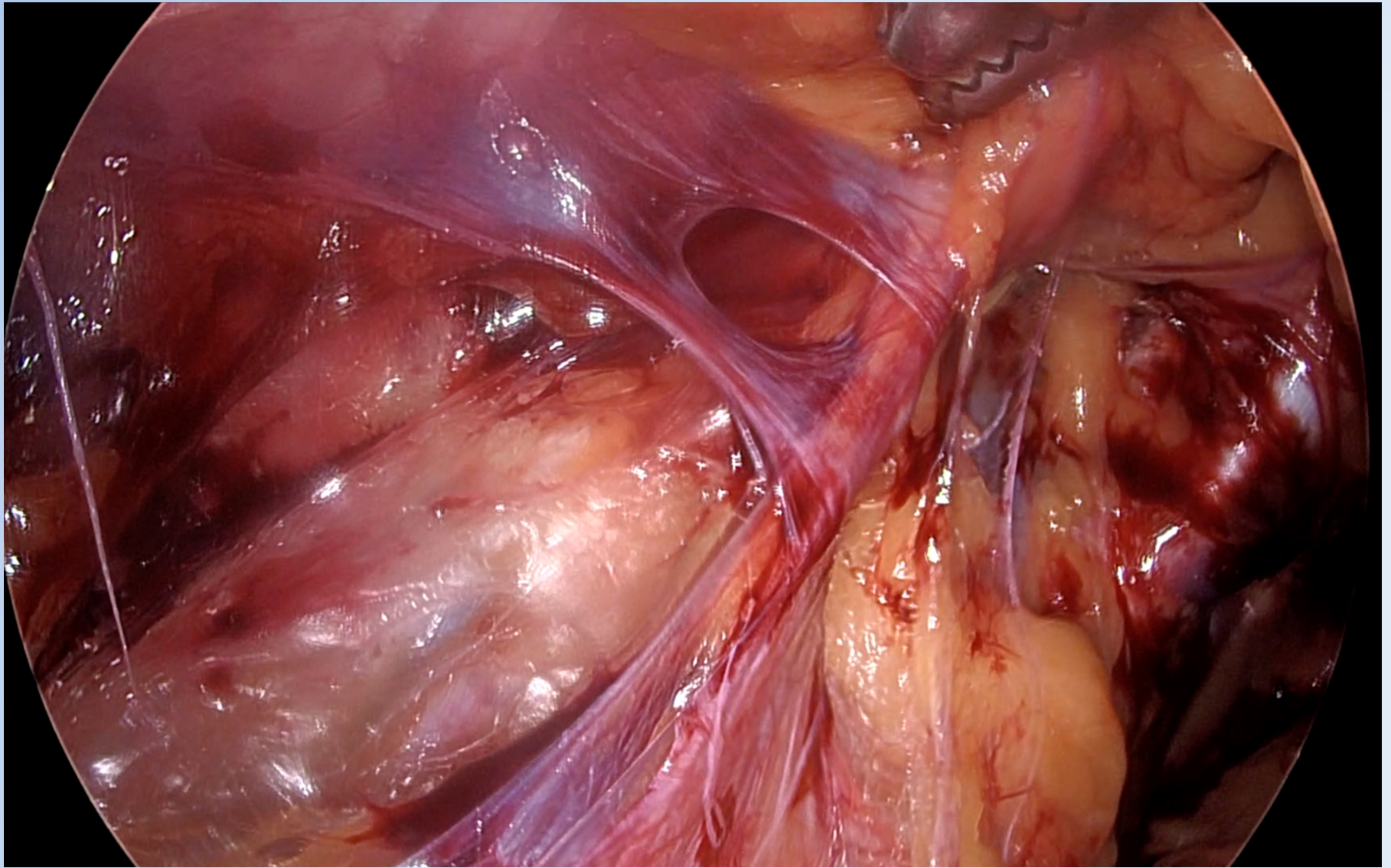
Would doing cases in an ASC allow you to perform more cases in less time increasing your efficiency and reimbursement?

If your answer was 'Yes' to either - TEPP

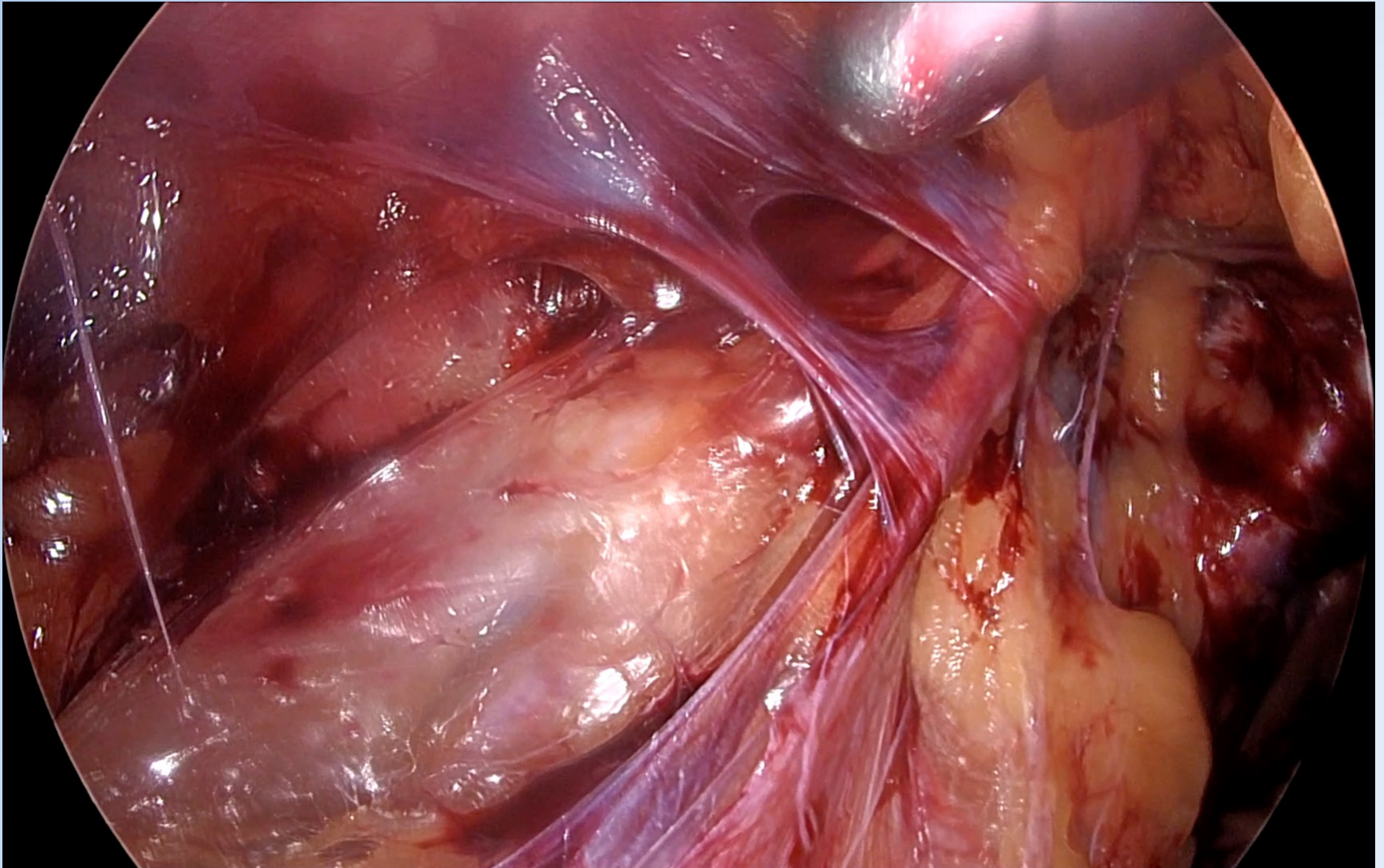
- Medicare Reimbursement CPT 49650: \$475
- CPT 49650 wRVU: 4.63
- ASC's have faster turn over times
- ASC's allow utilization of two rooms easier than a hospital
- TEPP is always less OR time
- Doing inguinal cases on a robot at a hospital is not as time efficient
- ASC's have ownership options

Insurance Pressures

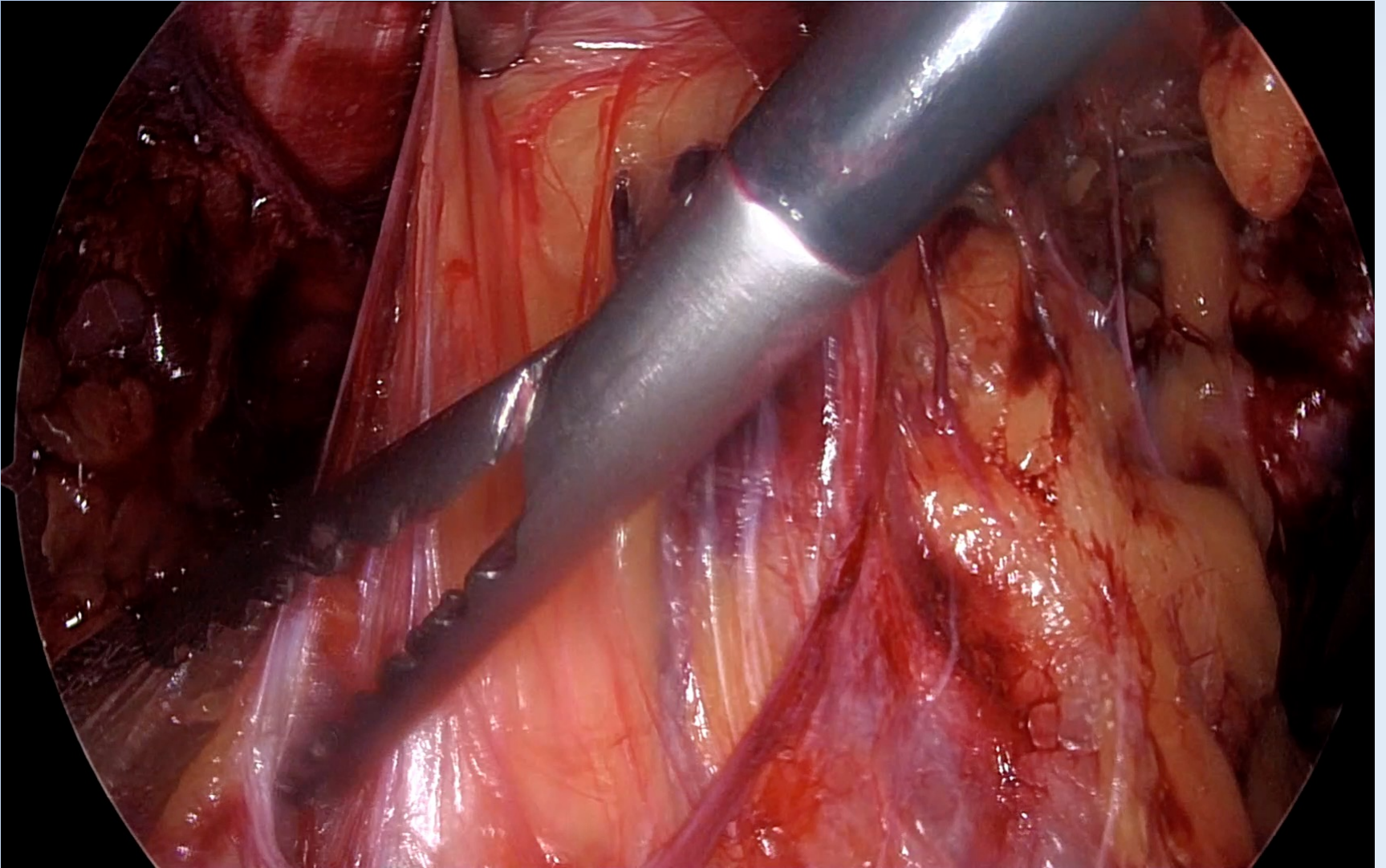
- Some insurance carriers in our area are not authorizing inguinal hernia repairs in a hospital setting
- Few in-network ASCs have a robot available
- Several colleagues have asked to re-learn TEPP/TAPP



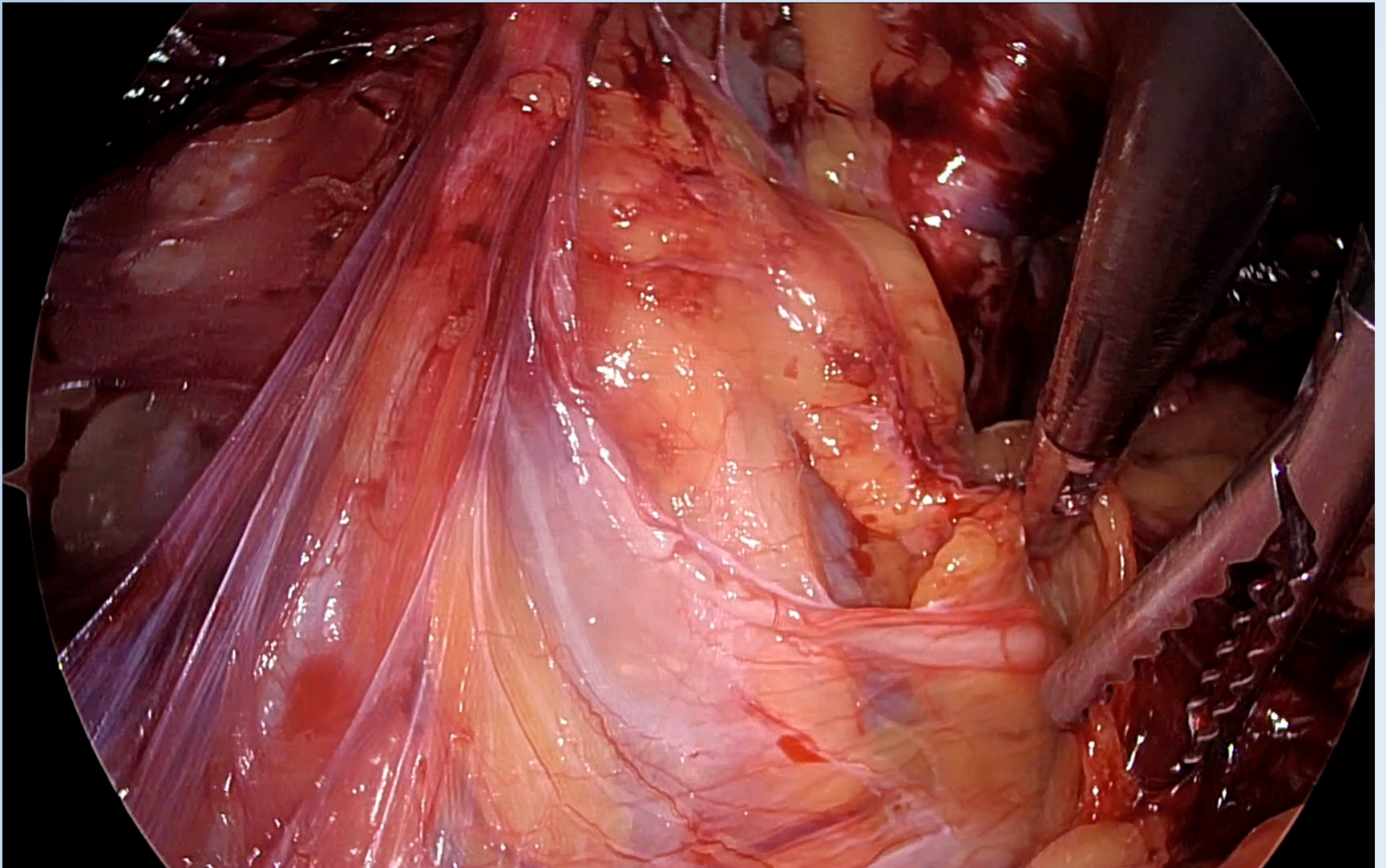
TWO LAYERS OF TRANSVERSALIS



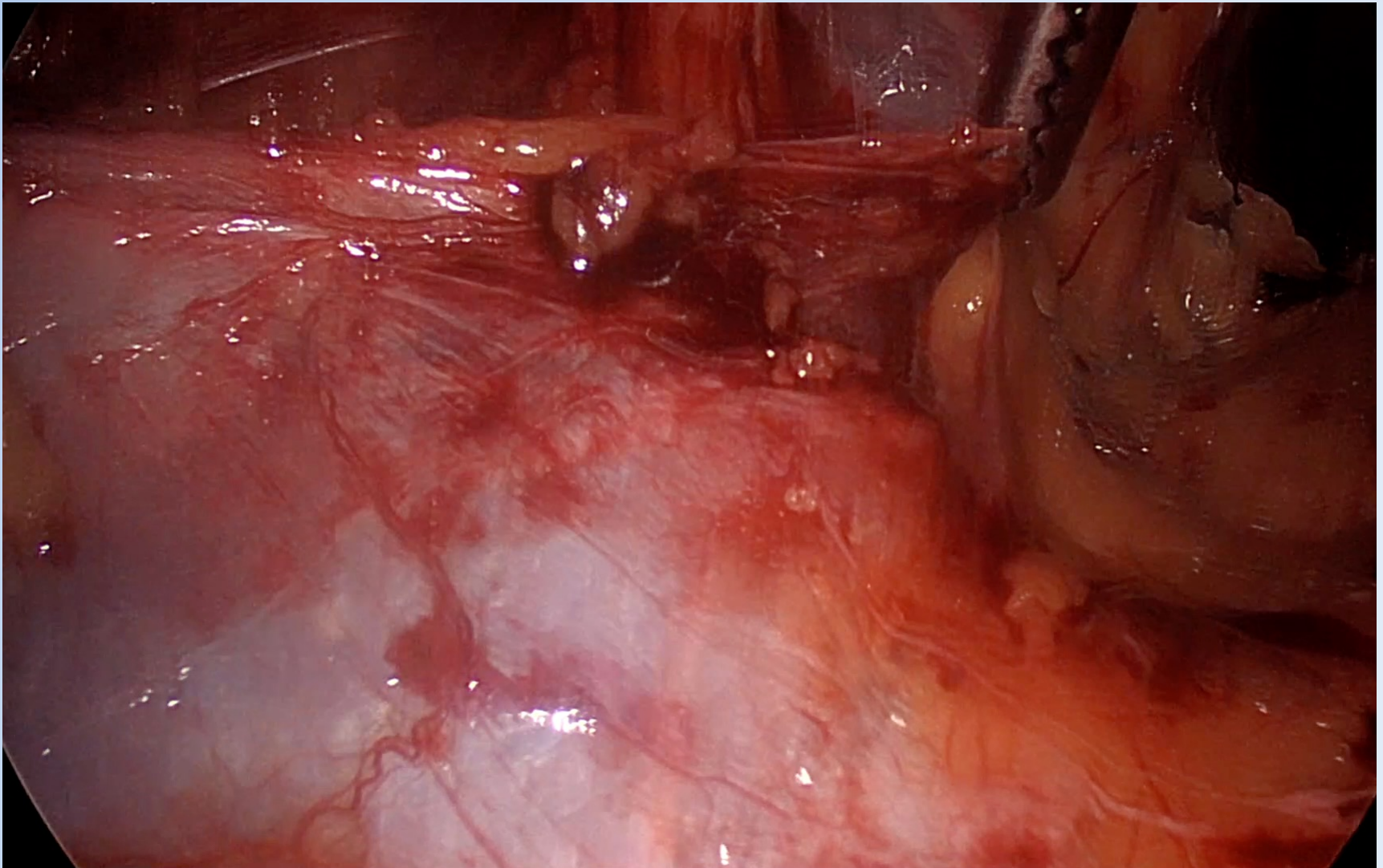
TWO LAYERS OF TRANSVERSALIS



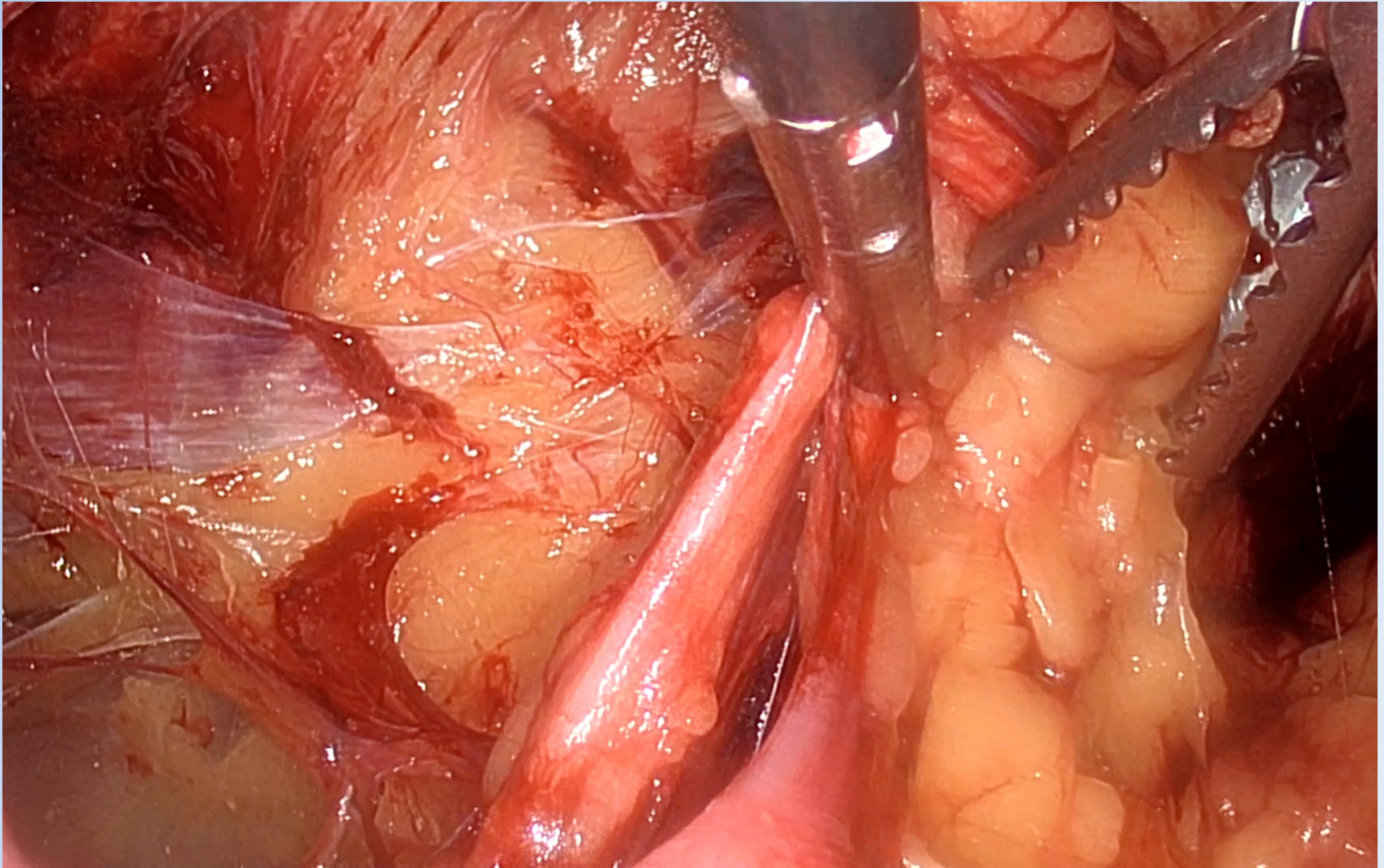
TWO LAYERS OF TRANSVERSALIS



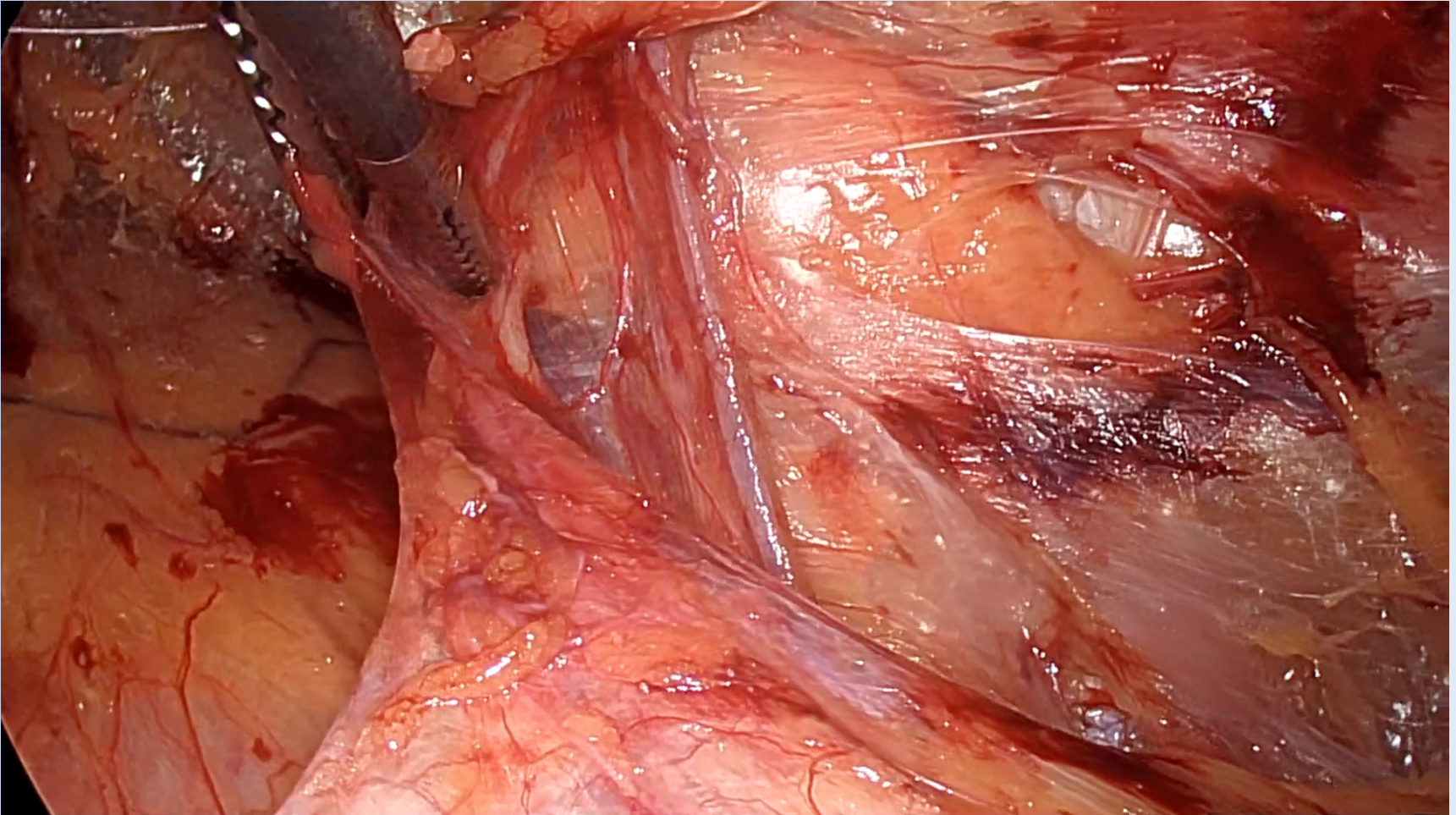
TWO LAYERS OF TRANSVERSALIS



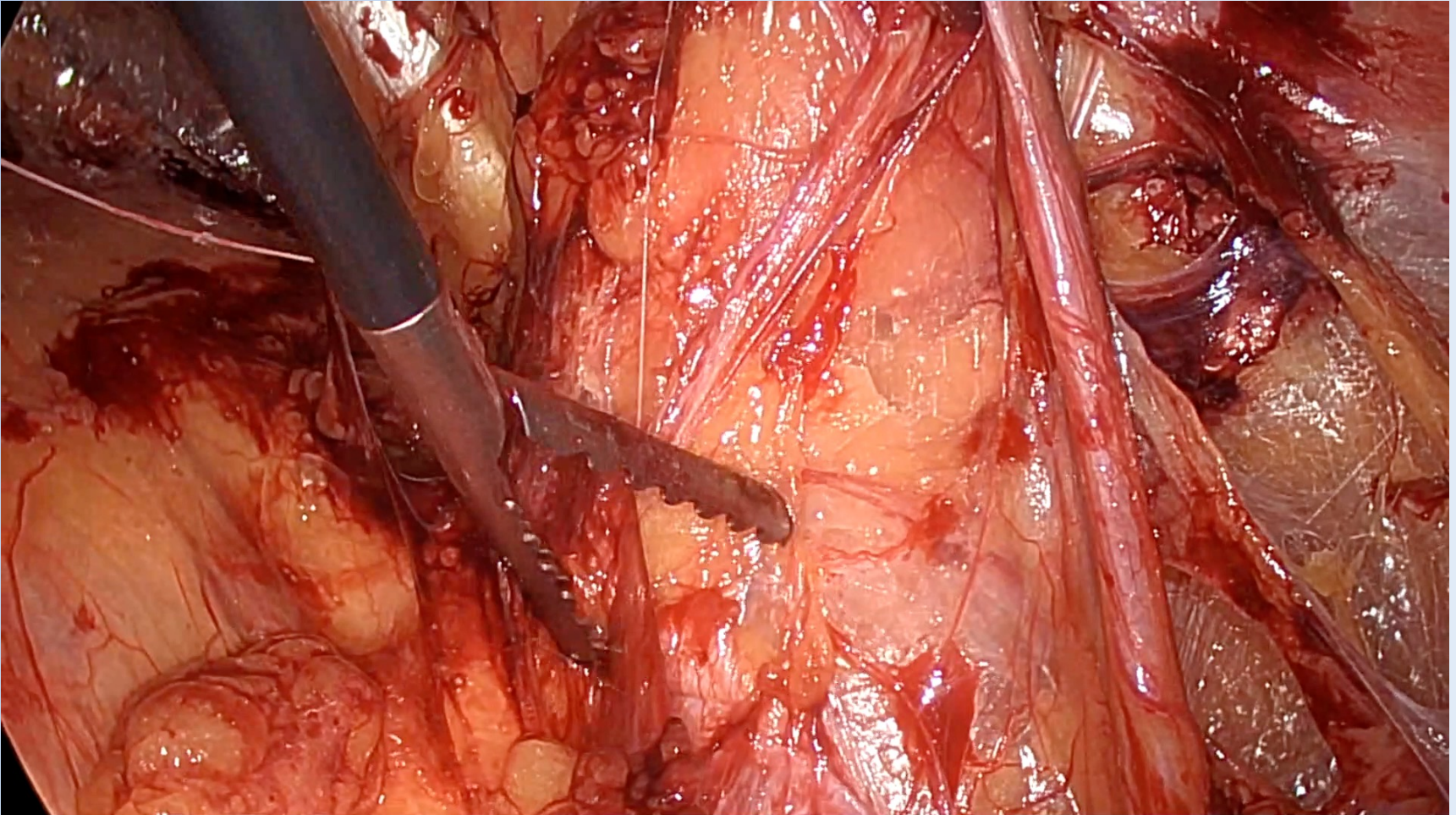
TWO LAYERS OF TRANSVERSALIS



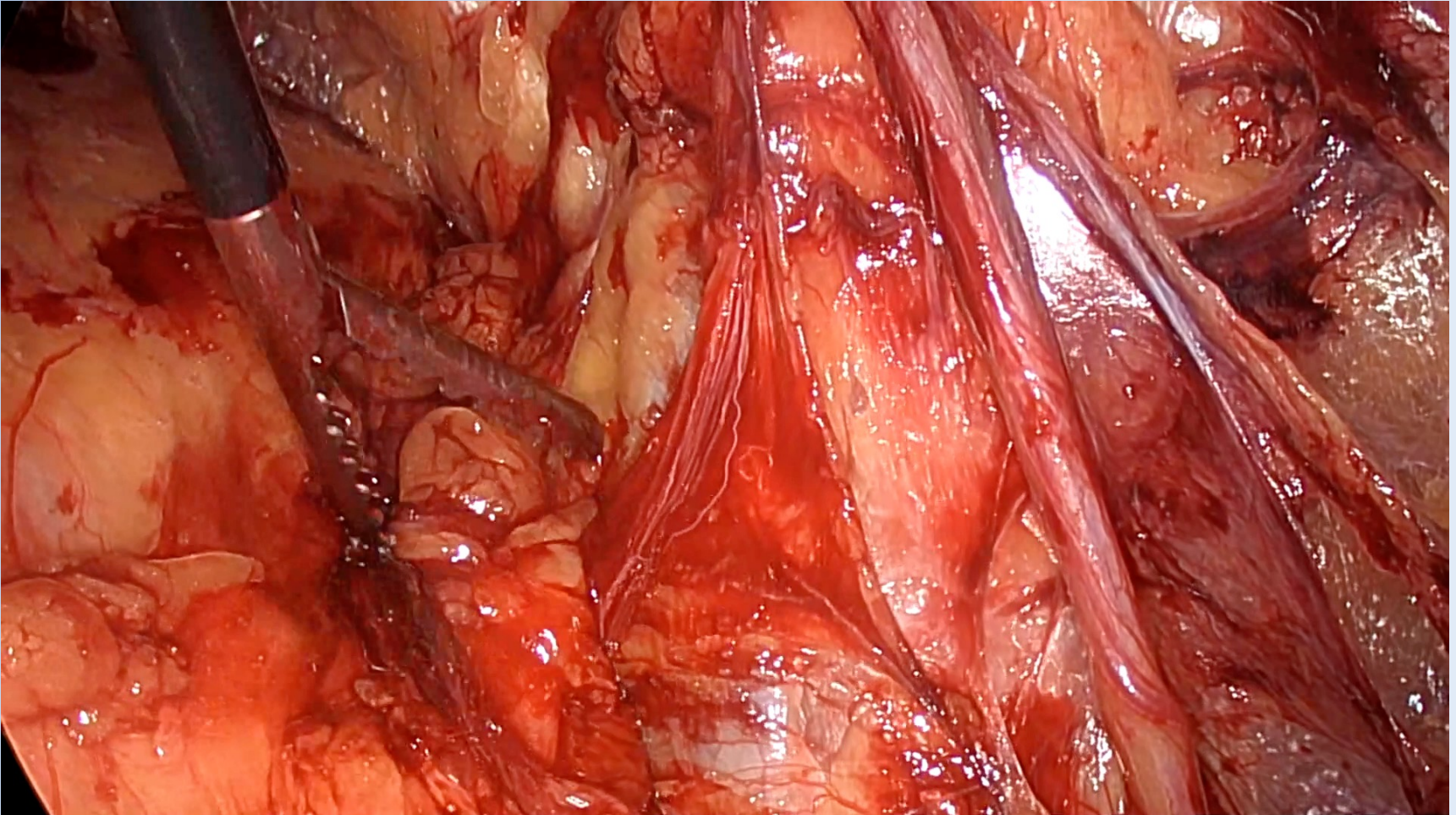
TWO LAYERS OF TRANSVERSALIS



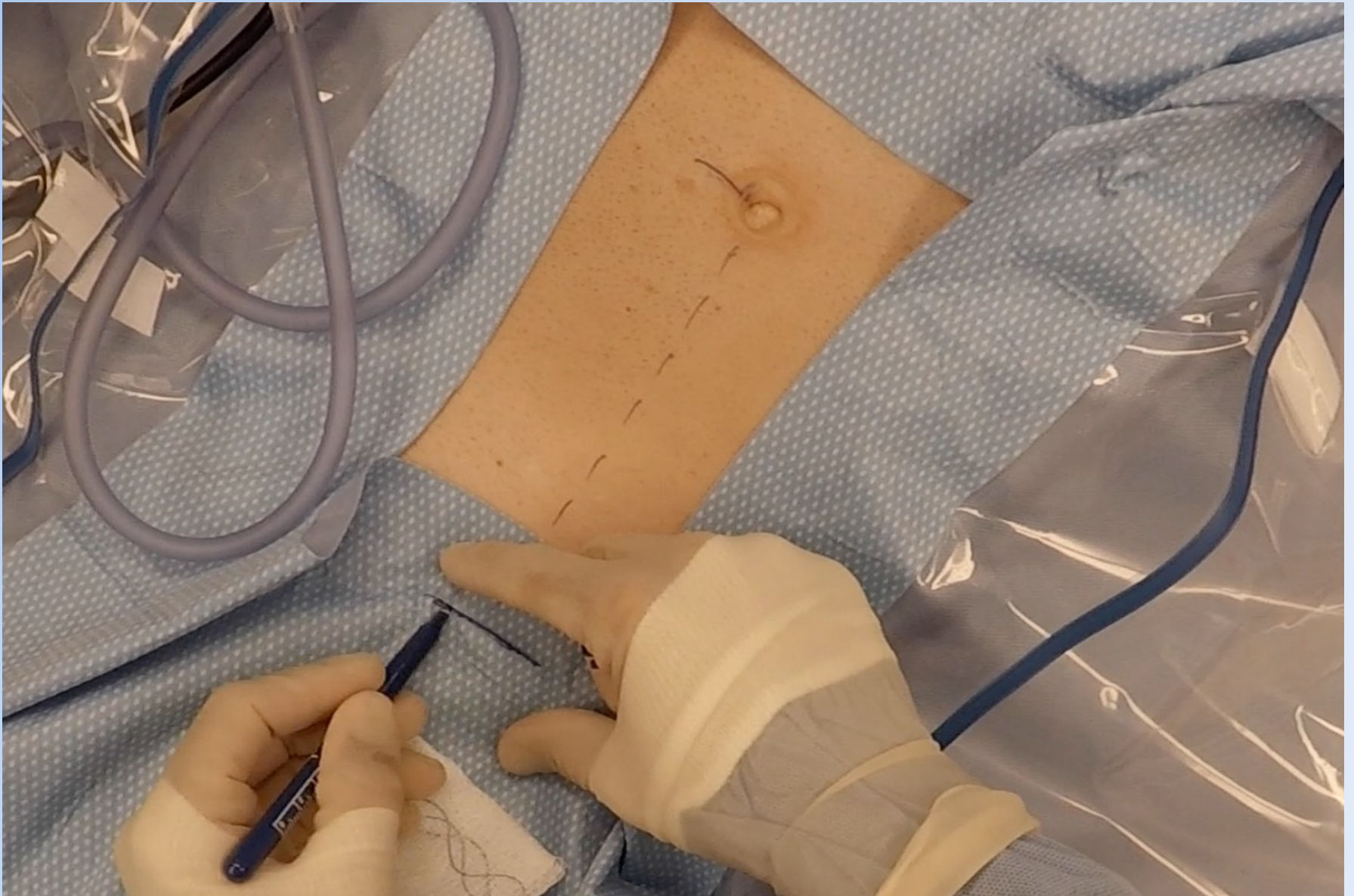
TWO LAYERS OF TRANSVERSALIS



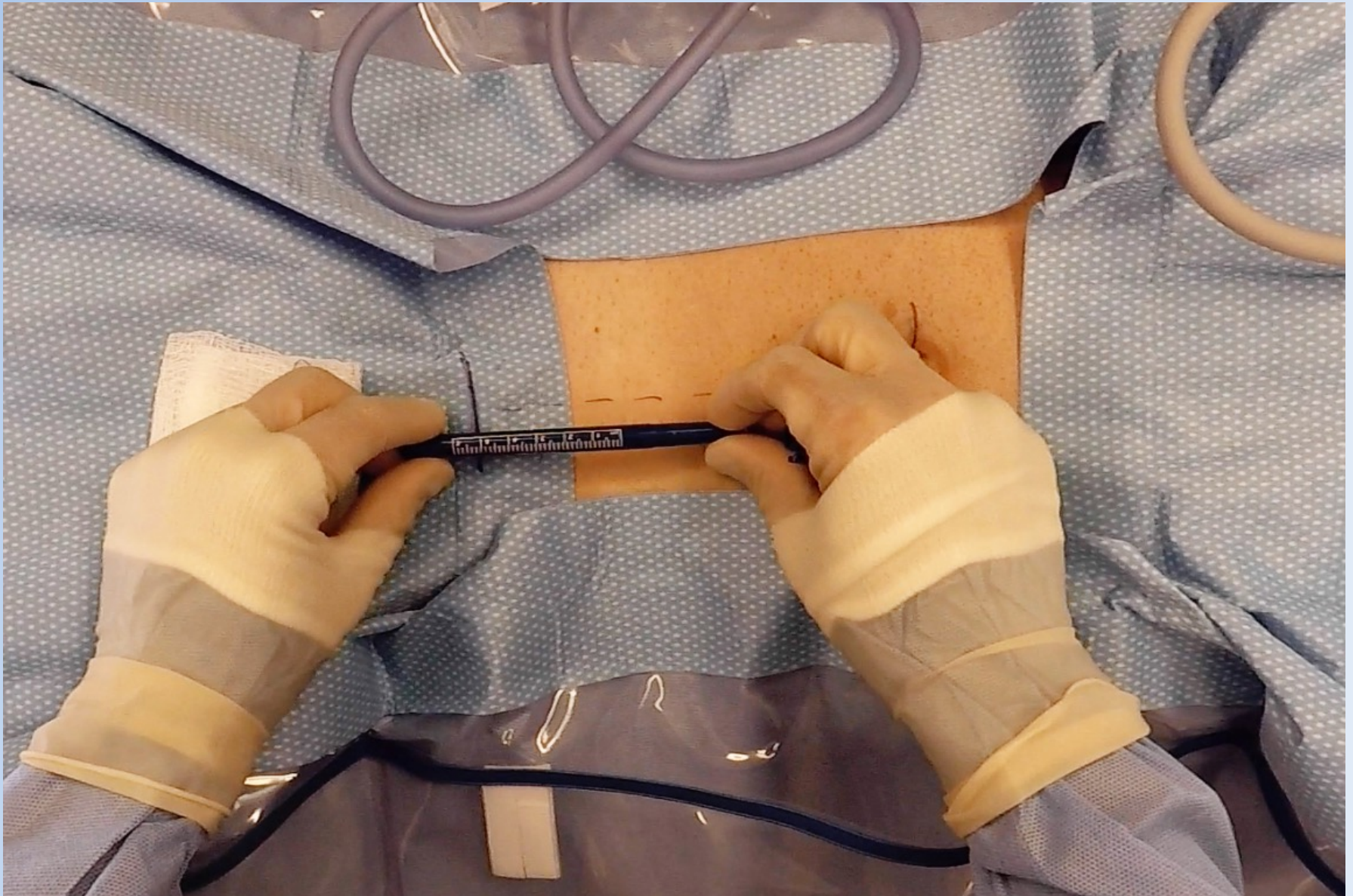
TWO LAYERS OF TRANSVERSALIS



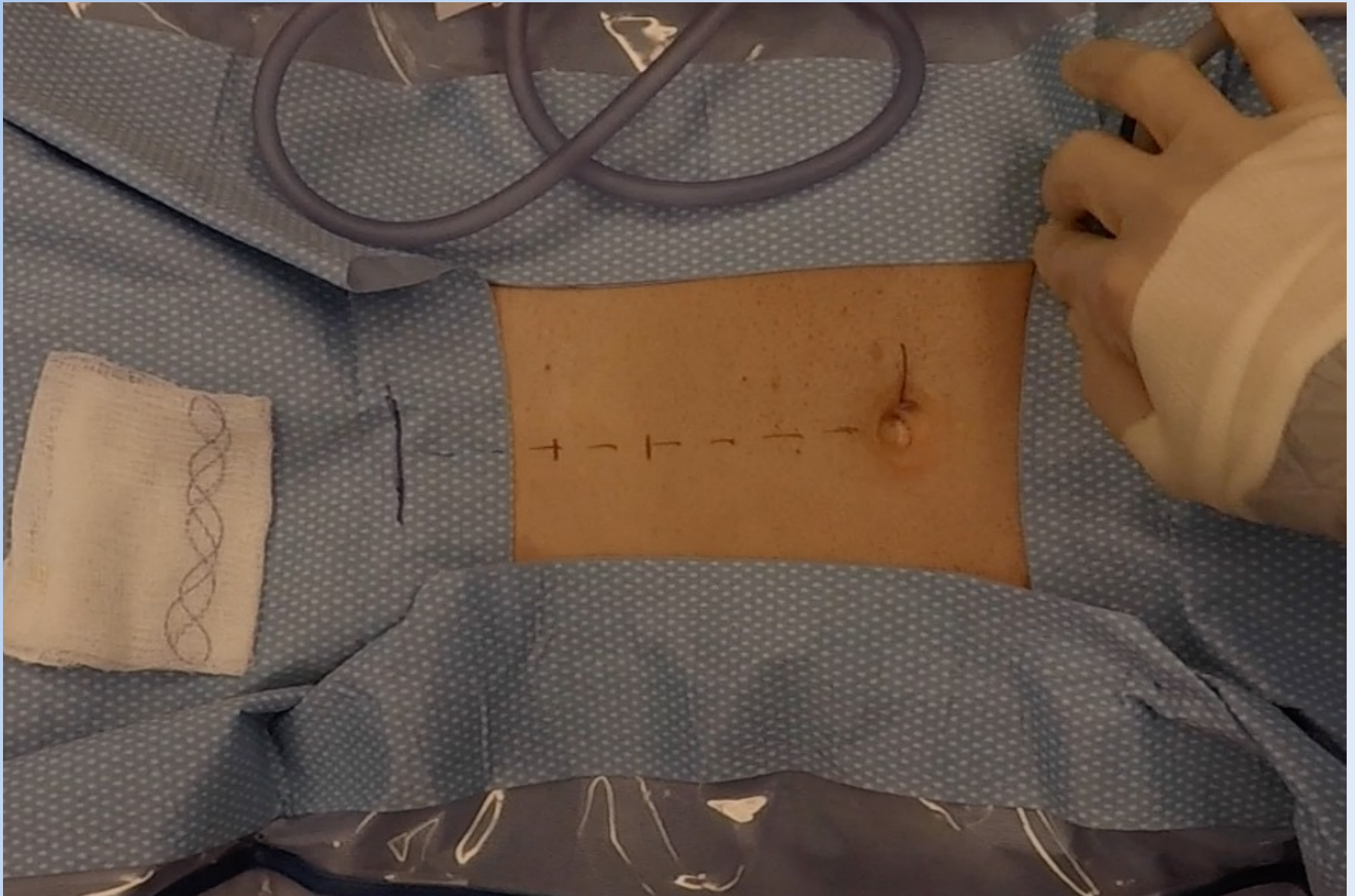
TWO LAYERS OF TRANSVERSALIS



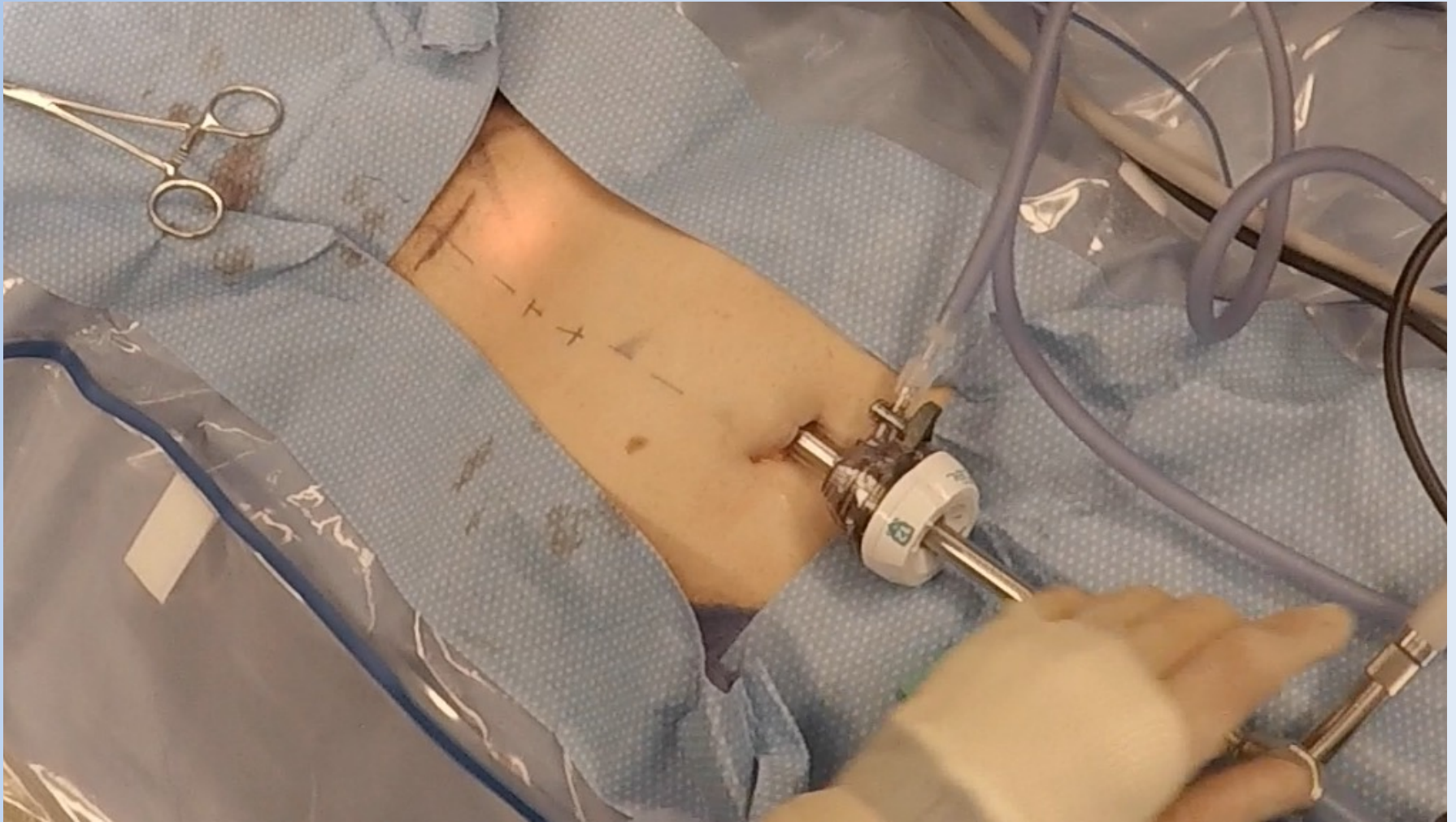
NO BALLOON



NO BALLOON

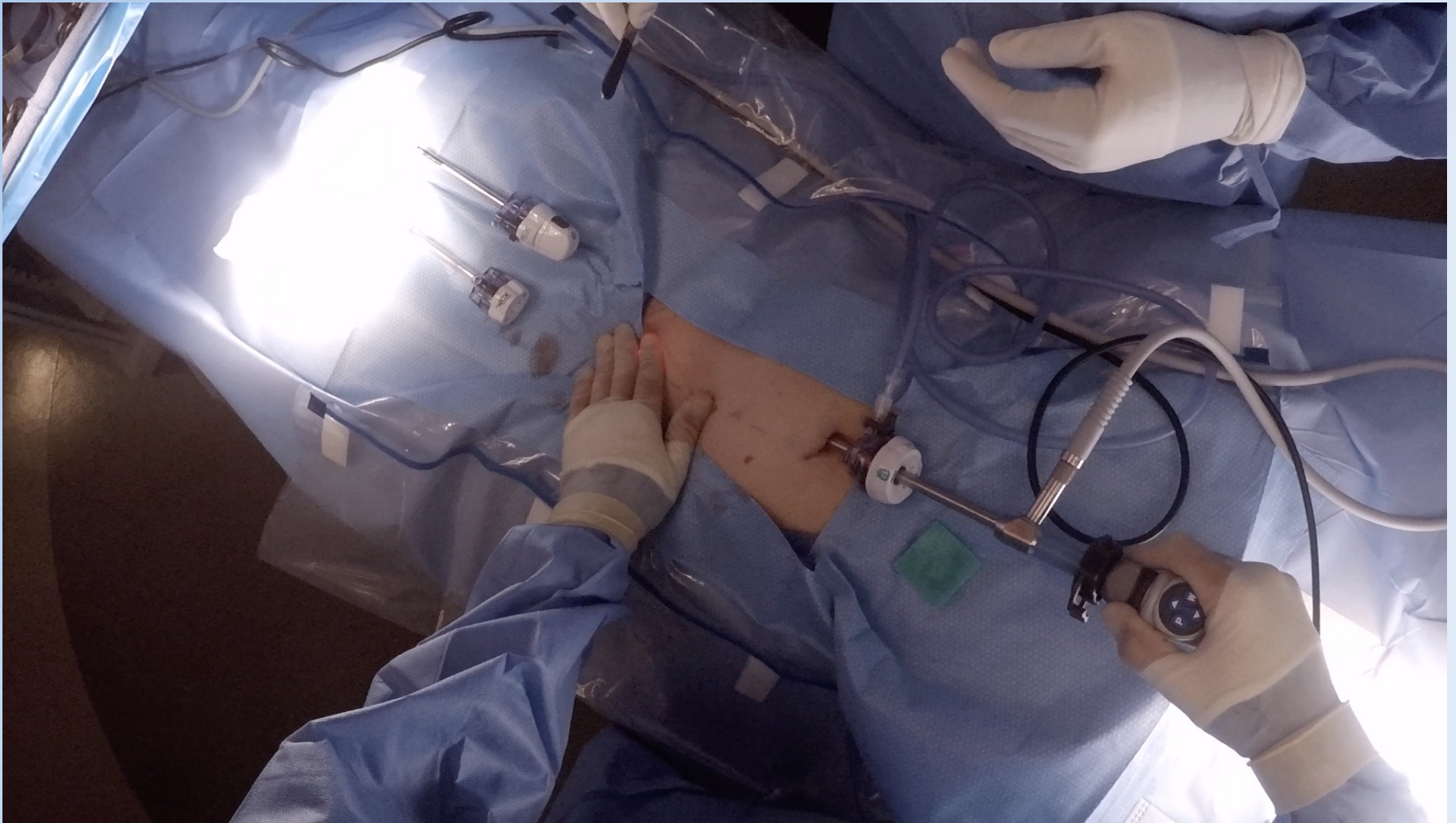


NO BALLOON



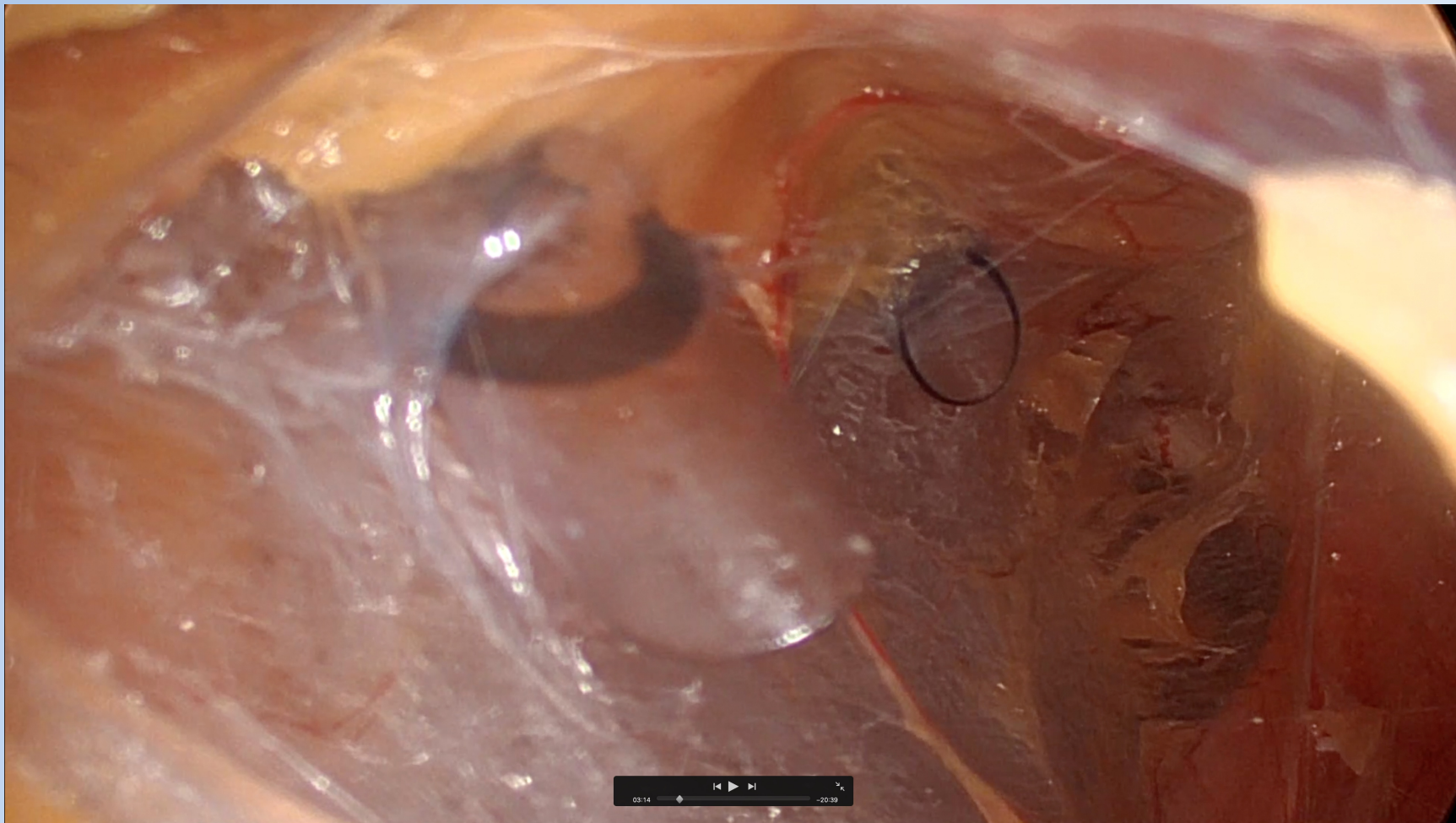
- 11mm trocar – gas
- Advance to the pubic bone

NO BALLOON



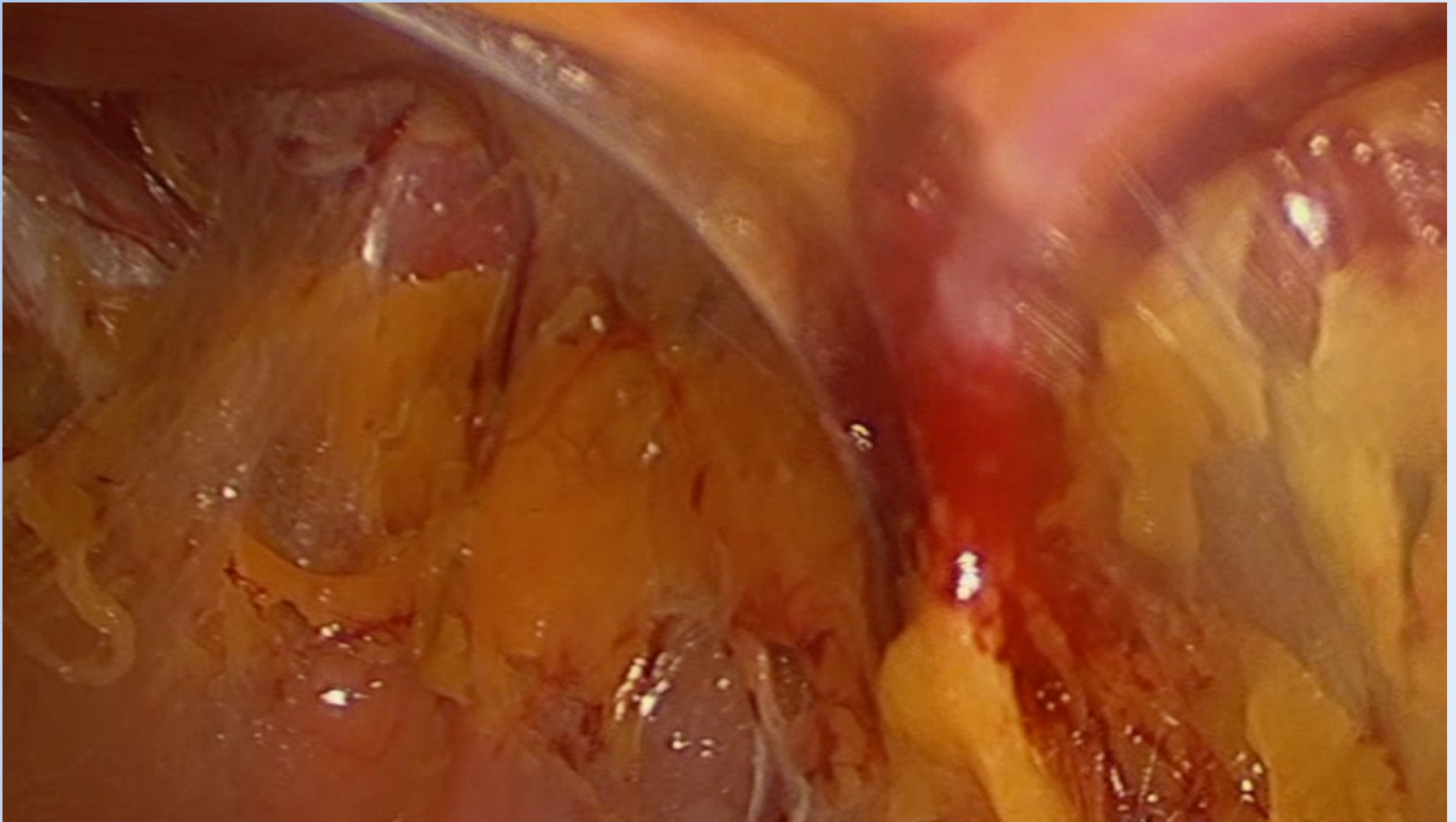
“Row the boat” about 1cm off the anterior abdominal wall

NO BALLOON



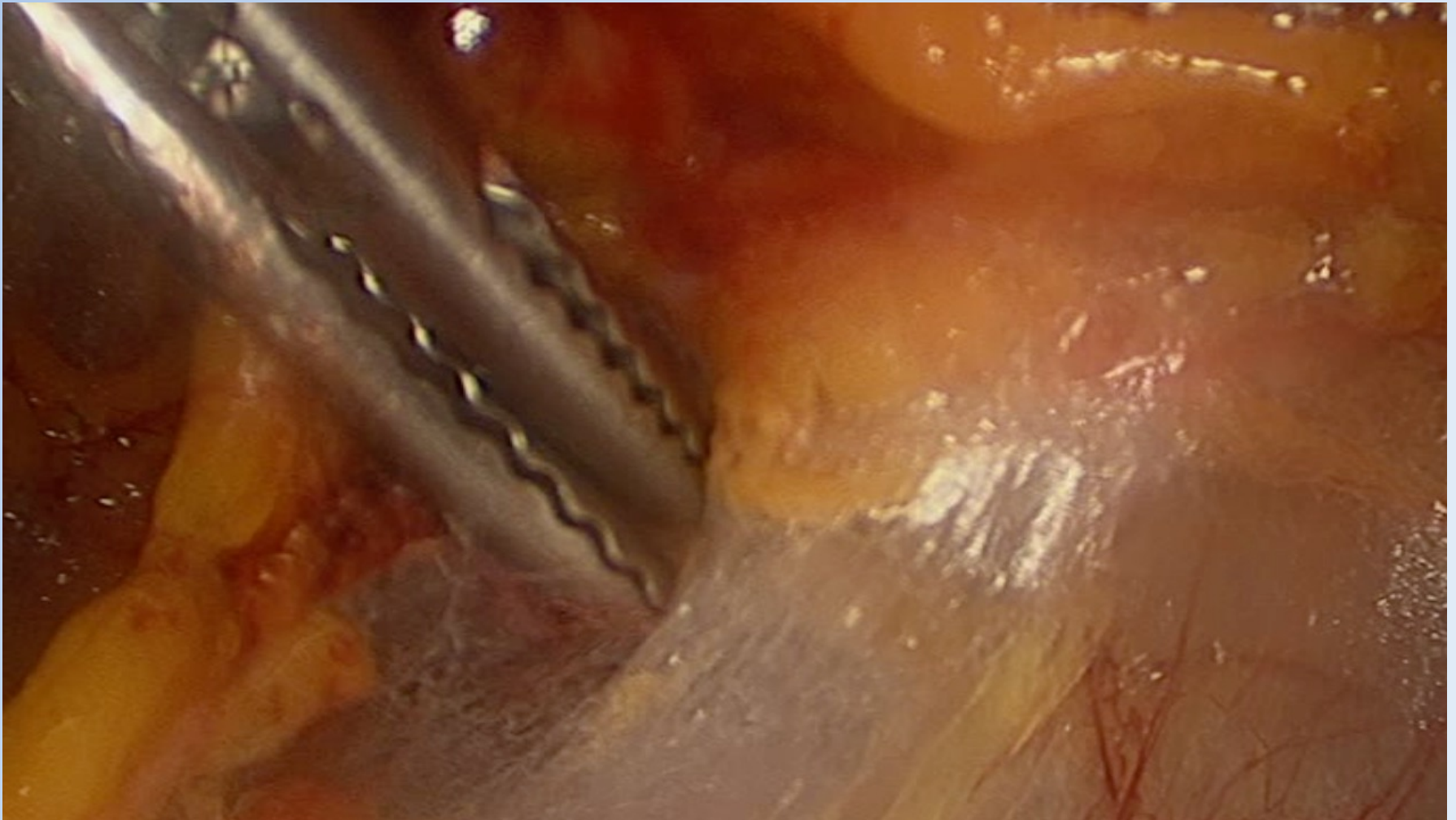
Small tunnel so place the 5mm trocars at the marked locations

NO BALLOON



- Place the inferior David & Geck up to the camera and sweep
- Keep inferior epigastrics against the abdominal wall with the superior D&G

NO BALLOON



- If you're looking lateral, there isn't much you can damage
- Large wide sweeps just below the inferior edge of the posterior rectus sheath

NO BALLOON

Inguinal hernia cases in the QC in 2023

Total Number of Inguinal Cases	5201	100%
Number of Laparoscopic Cases	1365	26%
Number of TEPP Cases	803	59% (15.4%)
Number of TEPP w/ dissecting balloon	453	56% (8.7%)
Number of TEPP w/o balloon	350	44% (6.7%)
Number w/o balloon which were not me	91	11% (1.7%)

ACHQC Quality Improvement Summit 2024

Todd S. Harris
Newport Beach, CA